A. Goldmann, MD, Lemgo, Germany °

D. Wassenberg, MD ° W. Hiller, MD °
C. Mau, MD ° K.-P. Grigat, MD °

Staging of Non Small Cell Lung Cancer (NSCLC) with F-18 FDG PET

ECR 2003

15th European Congress of Radiology
March 7 - 11, 2003, Vienna, Austria



PURPOSE

To show the purpose of the value of preoperative F-18 FDG PET in patients with bronchogenic carcinoma, we fortunately no longer depend on preoperative plain chest films alone.

This case shows no sign of carcinoma in 1996, whereas in 1998 a suspect intra-pulmonal nodule was detected which finally turned out as bronchogenic carcinoma. Could spiral CT and PET have shown an earlier diagnosis?

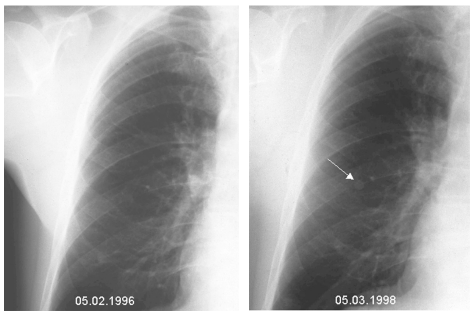

Bronchogenic carcinoma is the most common carcinoma in men. Every year in the US 171500 new cases appear. The rate of new cases in men is stable while the incidence of bronchogenic carcinoma in women is rising every year about 3%. The main reason is cigarette smoking which is getting more and more common in women. In Germany every year 37500 new cases of bronchogenic carcinoma appear, 80% of them are Non Small Cell Lung Cancer.

Therapy strongly depends on the local extend of the cancer and on the presence of distant metastases.

Curative therapy of choice in bronchogenic NSCLC is surgical resection, which is possible in N2 disease, while N3 disease and patients with distant metastases do not profit from operation. Purpose of this study is therefore to find out the value of preoperative F18 FDG-PET in the differentiation of N2 from N3 disease.

METHODS AND MATERIALS

Patients

For this reason 68 patients with suspected or histological proven NSCLC in a clinical operable situation were examined. Patients with hyperglycaemia, neoadjuvant chemotherapy and known distant metastases were excluded from the study.

Technique

All patients underwent CT and PET scanning. CT was performed with spiral CT in all cases. Examination area was the thorax from the lung apex till the adrenal glands with a slice thickness of 5 mm and a pitch of 1.5 in one breathold. Contrast enhancement was performed by a power injector with a contrast flow of 2 ml/s. Depending on the weight of the patients usually 100 ml of ultravist 300 was administered intravenously. A lymph node was interpreted as suspect depending on the lymph node size in different locations accordingly to the criteria of Webb et al published in the Journal of Computer Assistant Tomography 1993.
The PET examination was performed as a whole body examination with a Siemens ECAT Scanner Type 951/31. Emission and transmission corrected data were aquired and by standard back projection techniques axial, coronal and sagital sections were reconstructed. A lesion was interpreted as malignant if the focal uptake was that compared of brain. The images of both modalities were read in consensus by 2 experienced radiologists or specialists in nuclear medicine. No histopathological data were available at the time of interpretation.

Diagnostic Course

All patients included in the study had a thorougly anamnesis and physical examination. A complete blood status and test of lung function was also mandatory as abdominal ultrasound, bronchoscopy, MRI of the brain and as formerly mentioned Spiral CT. In Case of suspected distant metastasis additional imaging tests and sometimes biopsy was performed.

Therapy

If the results of this test showed a TNM classification up to T3N2M0 i.e. a clinical stage of up to IIIA according to the Union International Contre le Cancer thoracotomy with extensive lymph node sampling was performed.

If there was a disconcordance of the results of CT and PET mediastinoscopy was performed. In cases of N2 disease surgery was performed.

In cases with a clinical stage higher than IIIB conservative treatment was performed.

According to the American Thoracic Society Mapping System histopathologic results were correlated with CT and PET on a station by station basis.

Results were statistically evaluated by the χ^2 - Test.

RESULTS

PET showed the nature of all primary lesions and correctly staged N3 disease in all patients. In one patient unknown distant metastasis was detected. In this patient the originally planned thoracotomy was cancelled.

This is a case were CT showed a large praetracheal lymph node metastasis of this peripheral Non Small Cell Lung Cancer which was interpreted as ipsilateral that means N2 disease. PET changed this opinion which was surgically proved. This means we have a case were CT lead to a down staging of this N3 patient

CT understaged

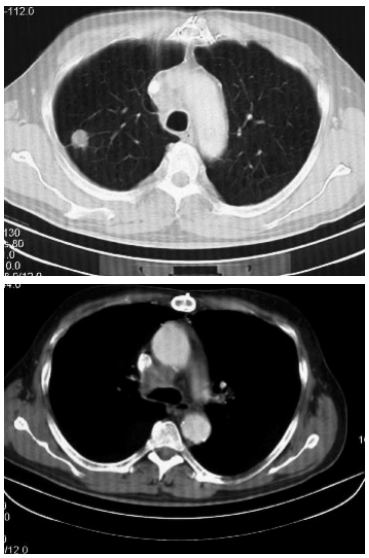

PET correct

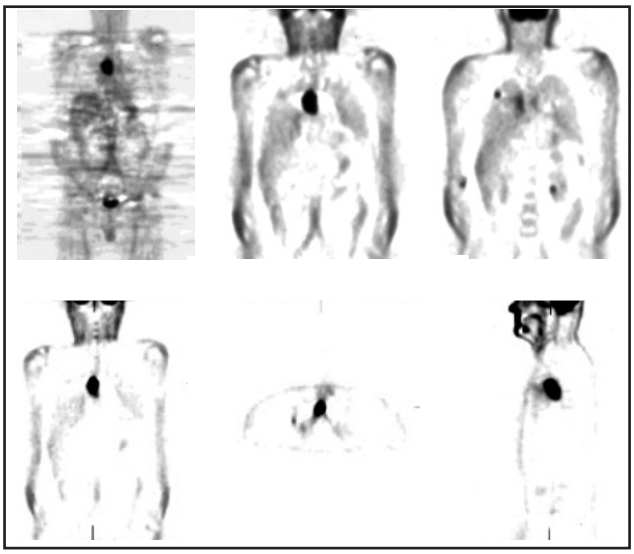

Besides this case of CT downstaging we had 3 patients were CT overstaged N2 disease as N3 disease because of unspecific lymph node enlargement. Here PET had the correct diagnosis with the consequence of surgical potential curative therapy for the patients.

This is one case were CT overstaged a reactively enlarged lymph node as N3 disease, while PET shows no activity in this lymph node indicating N0 disease.

CT overstaged

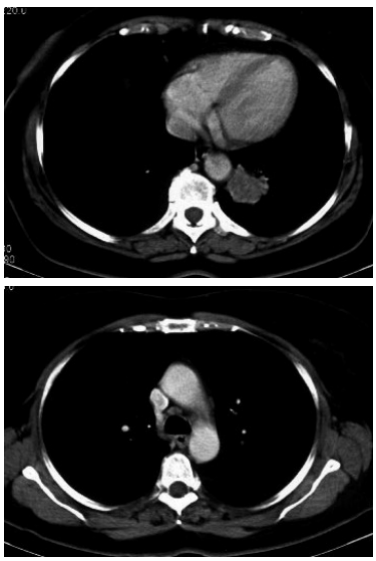

PET correct

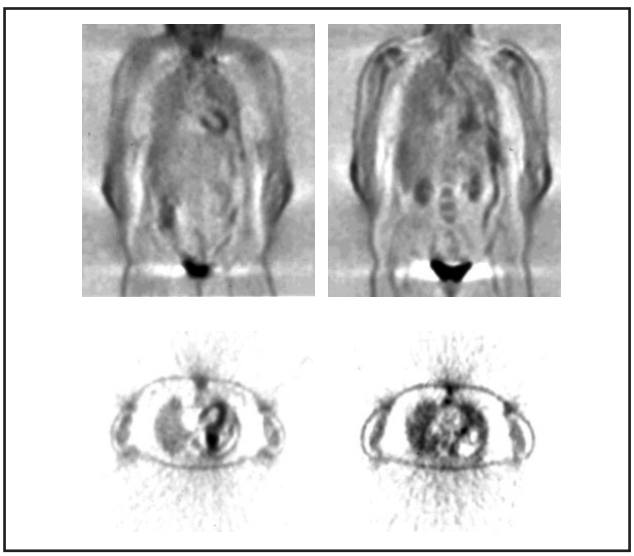

Alltogether 237 lymph nodes were examined and the results show a sensitivity of PET for hilar and mediastinal lymph nodes of 91% compared to a sensitivity of CT of 62%.

Specificity of PET was 96% and 80% for CT.

These were statistically significant differences between PET and CT in staging lymph node metastases.

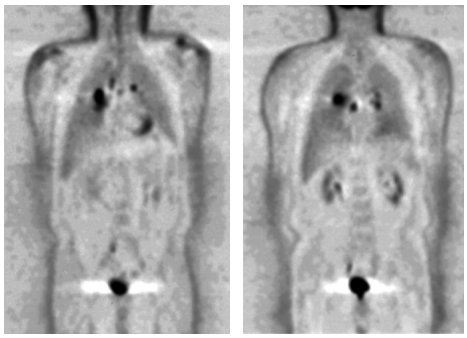

N3 Disease

This case shows a patient with N3 disease which could not be operated.

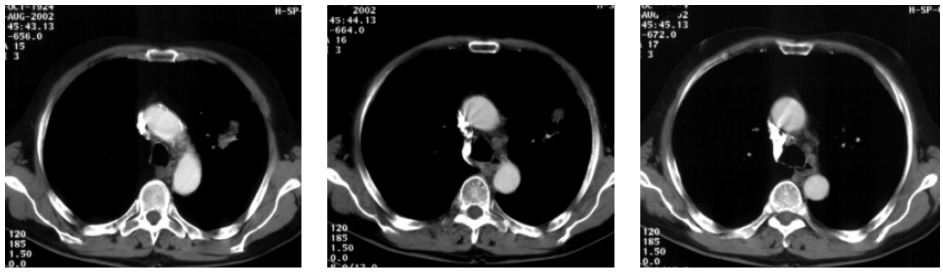

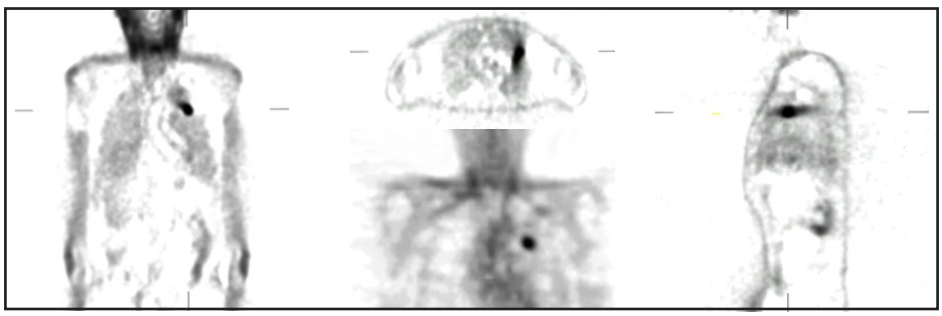

N2 Disease

This patient was operated due to the results of negative PET findings although CT indicated N3 disease of this peripheral left upper lobe NSCLC.

PET results were confirmed by histopathologic examination following thoracotomy.

CONCLUSION

F-18 FDG PET scanning is superior to spiral CT for staging of non-small cell lung cancer.

PET has the potential to determine the therapeutic course because of the correct differentiation between N2 and N3 disease and the sensitive proof of distant metastasis.

Results of CT can exclude operable patients from surgery as the only curative therapy because CT tends to up-stage unspecific lymph node enlargement.

Correct diagnosis of all benign tumors by PET facilitates the operative procedure and reduces invasiveness!

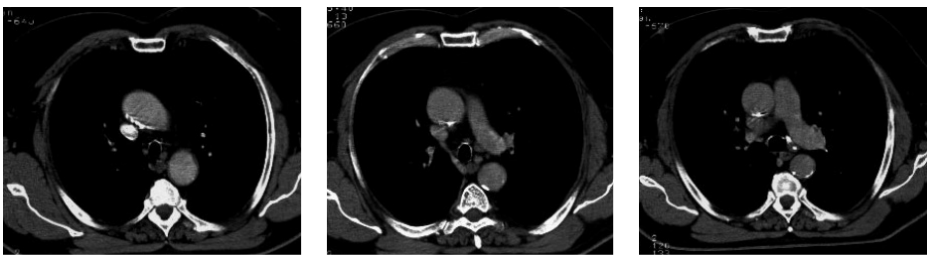

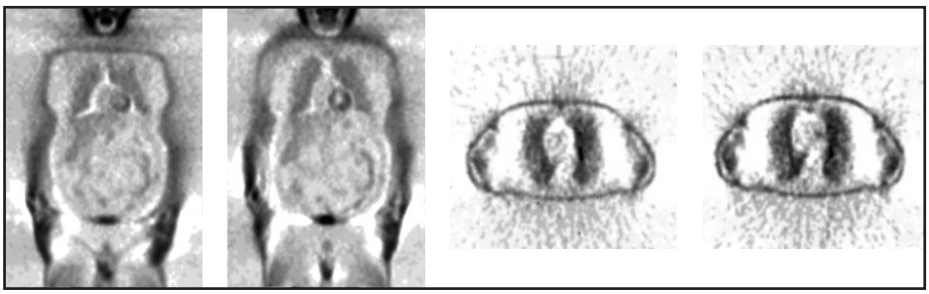

Pitfalls

In this case negative PET indicates the absence of primary tumor in this patient with haemoptisis for 6 weeks.

Bronchoscopy found a carcinoma in situ which was operated.

This example shows the limit of modern diagnostic procedures which cannot replace clinical experience.